

Prostatic infarct: A case report and review of literature

Mahmoud R. Hussein¹*, Ahmed Abou Alyosr Mohammed², Eman E Abu-Dief³

¹Departments of Pathology (Assuit University), ²Urology (South Valley University) and

³Histology (Sohag University)

Corresponding author*: Dr. Mahmoud Rezk Abdelwahed Hussein, Department of Pathology, Faculty of Medicine, Assuit University, Assuit, Egypt.

Email address: frcpath17@gmail.com

Abstract:

This study reports a 56 years old male patient with a history of sudden urinary retention and high level of prostatic specific antigen. Suprapubic transvesical prostatectomy was done and revealed enlarged prostate with a large, circumscribed area of infarction. On histology, a well-circumscribed zone of coagulative necrosis, haemorrhage, surrounding reactive squamous nests with reactive atypia (prominent nucleoli, and frequent mitoses) and foci of squamous metaplasia) was identified. The diagnosis of prostatic infarct was established. A review of literature was presented.

Keywords: Prostate, infarcts, and necrosis

1 Introduction:

The prostate gland like any other organs (such as the heart, retina, and brain) is subject to ischemia and infarction. An infarct of the prostate is usually reported in 25% of specimens removed for benign nodular hyperplasia. It is associated with prostatic swelling with sudden onset of urinary retention, haematuria and a markedly increased prostatic specific antigen (PSA). This study reports a 56-year-old male presented with sudden history of urinary retention, haematuria and high PSA level (80 ng/mL). Suprapubic prostatectomy was done (Filippini Battistelli 1962). Grossly, area of infarct was seen. On histology, there were composed of a coagulative necrosis, haemorrhage, reactive nests of immature squamous metaplasia with visible nucleoli,

squamous atypia, and mitoses (ranging from 4-10), cellular debris without neutrophils, corpora amylacea, and rings of collagen around squamous islands. Based on the present case and a review of the literature, prostatic infarct with worrisome atypia (resembling urothelial carcinoma) proved to be a rare lesion (Siano 1960) (Milord, Kahane et al. 2000; Tuncel, Uzun et al. 2005). The pathogenesis and diagnosis of prostatic infarcts as well as their distinction from urothelial carcinomas are discussed.

2 Case Report:

This investigation describes 56 years old male patient who presented with a sudden history of urinary retention and haematuria. The patient has been referred to Department of Urology of Assiut University Hospitals. His history was

unremarkable and did not contain previous complaint of ill health. General examination was unremarkable. Rectal examination revealed diffusely enlarged prostate and urethral catheter was introduced to relieve the obstruction. Radiological examination revealed enlarged prostate but unremarkable urinary bladder, ureters and kidneys. Suprabupic prostatectomy was done and the specimen was submitted for pathological examination. Grossly, the prostate was diffusely enlarged, with discrete, large nodules. The mean of the prostatic tissue was 120g. The cut section showed admixture of yellow-pink, soft tissue, oozing prostatic fluids (glandular hyperplasia) and gray, tough one (stromal hyperplasia). Also, a haemorrhagic, necrotic area (2.0 X 2.0 X 1.0 cm) was seen. Histological examination of hematoxylin-eosin stained sections revealed a coagulative necrosis, haemorrhage, reactive nests of immature squamous metaplasia with vesicular nuclei, pink cytoplasm, visible nucleoli, squamous atypia, modest mitoses (ranging from 4-10), cellular debris with or without neutrophils, corpora amylacea, and rings of collagen around squamous islands.

3 Discussion:

Prostatic infarct is seen in 0.07% of needle biopsies, 20% to 25% of specimens removed for benign nodular prostatic hyperplasia, and in 2.8% of total prostatectomy specimens. The infarcts are usually multiple and usually located in the central and/or middle concentric zones of the middle third of the prostate without a preference for a particular lobe (Brawn, Foster et al. 1994). The age range is 57-84 years and the average age is 71 years. These lesions have no proven associations with vascular disorders such as hypertension, and atherosclerotic coronary vascular diseases (Milord, Kahane et al. 2000). Also, their exact underlying aetiology is unknown. However, it may result from disturbances of blood supply or venous drainage, possibly by mechanical disruption or compression of the vascular spaces. The patients usually present with urinary retention and high sudden rise of PSA level (199-287 ng/mL)

(Milord, Kahane et al. 2000). Patients with acute prostatic infarcts have glands twice as large as those in patients without infarcts and are more prone to have acute urinary retention and gross haematuria.

Because the infarcts are often small and not close to the urethra, the symptoms may not be due to the infarcts but, instead, may be due to macroscopic enlargement of the prostatic gland containing them (Tuncel, Uzun et al. 2005). The infarct size ranges from 0.1-5.0 cm. In the acute phase, discrete foci of coagulative necrosis involve the epithelium and connective tissue. Grossly, they appear yellow or mottled with hemorrhagic areas and are somewhat firmer than the surrounding prostatic tissue. Histologically, three types of infarcts are recognised: i) earlier-aged infarcts with coagulative necrosis and recent haemorrhage; ii) intermediate-aged infarcts with reactive stroma and epithelium without necrosis; and iii) remote infarcts with replacement of the stroma by dense fibrosis with metaplastic glands (Filippini Battistelli 1962; Milord, Kahane et al. 2000). Healed infarcts can be identified by areas of dense scar formation and fibrosis. Nests of cytologically worrisome immature squamous metaplasia are usually seen adjacent to the sites of acute prostatic infarcts. These nests are composed of cells with abundant pink cytoplasm, vesicular nuclei, prominent nucleoli, and frequent mitotic figures ranging from 1-10. Some cases may be misdiagnosed as urothelial carcinoma.

Features helpful in separating infarcts from urothelial carcinomas include the presence of cyst containing cellular debris with or without neutrophils, corpora amylacea, and rings of collagen around squamous islands. Urothelial carcinoma usually lack these features (Siano 1960; Milord, Kahane et al. 2000). The squamous epithelial nests of prostatic infarct rarely show keratinization and can easily be distinguished from squamous carcinoma by their lack of pleomorphism and the localized nature of the process to the area immediately adjacent to the infarct. To summarize, this study reports a

case of prostatic infarct, associated with nests of immature squamous cells resembling urothelial carcinoma. The awareness of prostatic infarcts on the part of the pathologists and clinician and

their association with very high PSA level and atypical histology can prevent the misdiagnosis of urothelial carcinomas.

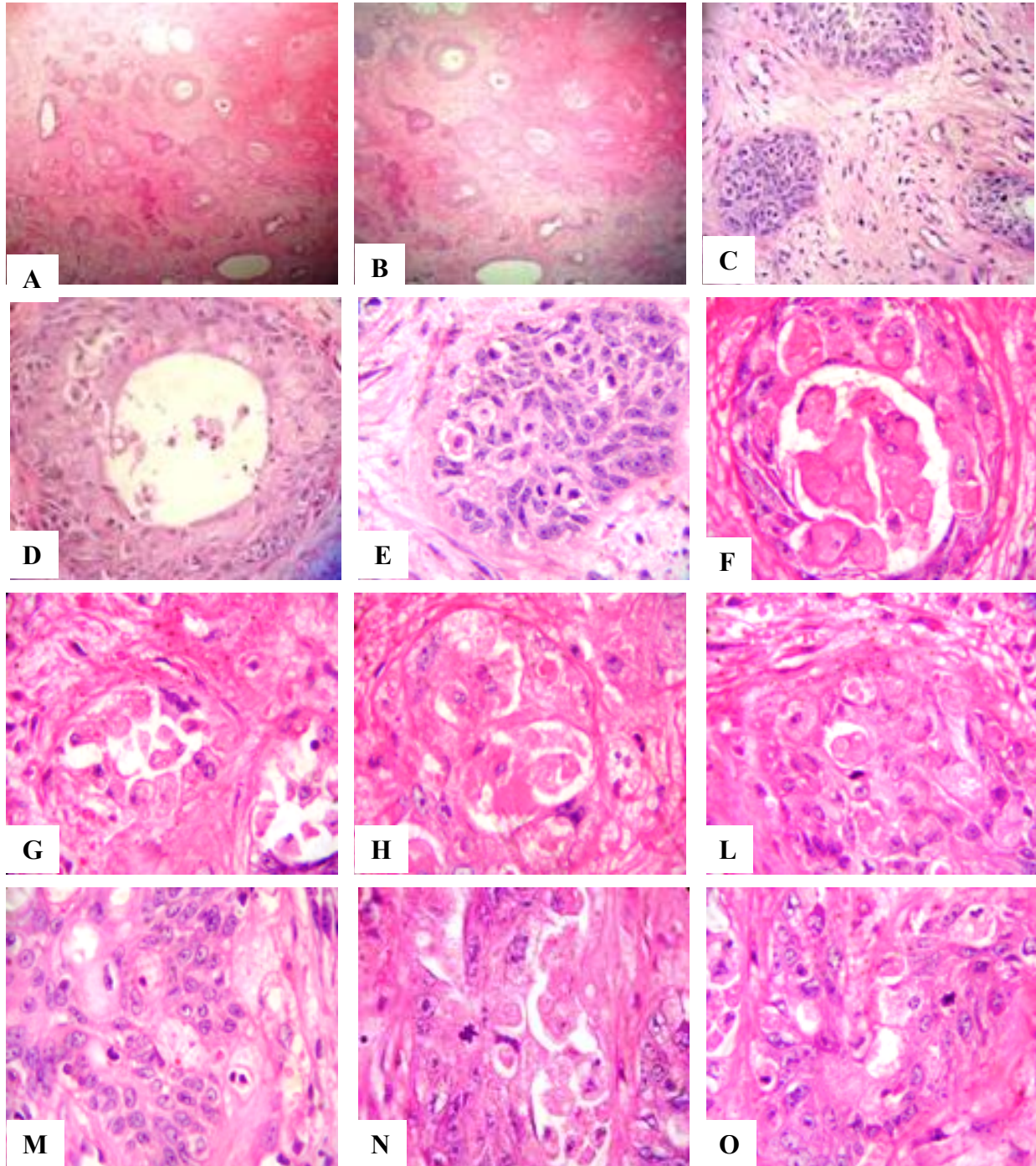


Figure 1: Histological features of prostatic infarct

A-L): The infarct is composed of coagulative necrosis, haemorrhage and nests of reactive squamous cells
 M-O): The reactive squamous cells are composed of sheets of cells with abundant pink cytoplasm, vesicular nuclei, prominent nucleoli, squamous atypia, modest mitotic activity, cellular debris without neutrophils, corpora amylacea, and rings of collagen around squamous islands

**Reference:**

Brawn, P. N., D. M. Foster, D. W. Jay, D. Kuhl, V. O. Speights, E. H. Johnson, K. S.

Coffield, M. L. Lind, R. Karl and B. Weaver (1994). "Characteristics of prostatic infarcts and their effect on serum prostate-specific antigen and prostatic acid phosphatase." *Urology* **44**(1): 71-5.

Filippini Battistelli, U. (1962). "[Infarct of the prostate.]" *Riv Patol Clin* **17**: 647-55.

Milord, R. A., H. Kahane and J. I. Epstein (2000). "Infarct of the prostate gland: experience on needle biopsy specimens." *Am J Surg Pathol* **24**(10): 1378-84.

Siano, J. C. (1960). "[Hemorrhagic infarct of the prostate gland.]" *Rev Argent Urol* **29**: 134-7.

Tuncel, A., B. Uzun, T. Eruyar, E. Karabulut, S. Seckin and A. Atan (2005). "Do prostatic infarction, prostatic inflammation and prostate morphology play a role in acute urinary retention?" *Eur Urol* **48**(2): 277-83; discussion 283-4.
